

## Summary Feedback

### ST1 – ST4 Teaching Programme 2024

#### Broadcast of Pre-recorded Session

#### **DKT FRCR 2B Practice Viva (Session 85)**

#### **DKT Spotlight Series Mastering CT in Acute Abdomen (2/2)** **(19<sup>th</sup> December 2024)**

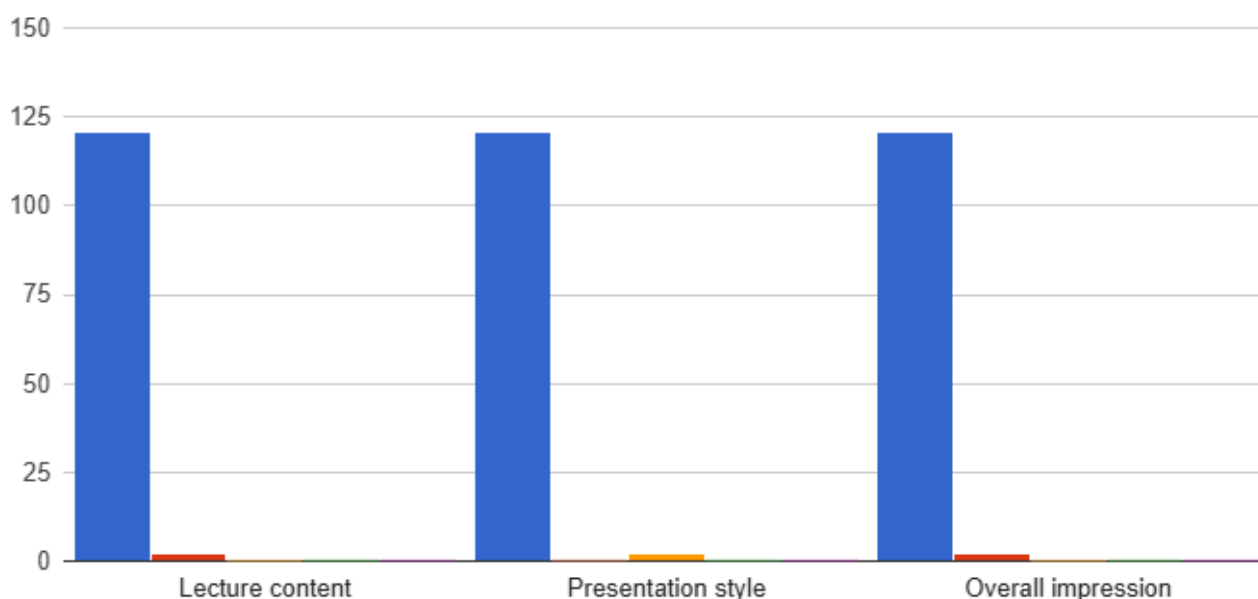
**Delivered By:**  
**(Sami Khan)**

#### Summary Points:

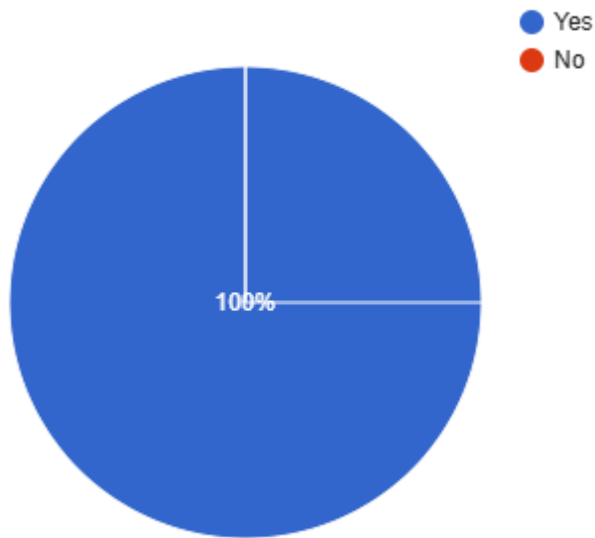
- ST1-ST4 teaching programme 2024 – FRCR 2B Practice Viva Session 85: 2 hours teaching time
- Total Attendees: 387 from 34 Countries (Algeria, Argentina, Australia, Bahrain, Bangladesh, Canada, Dominica, Egypt, Ghana, Hong Kong, India, Indonesia, Iraq, Jordan, Kenya, Libya, Malaysia, Myanmar, Netherlands, Nigeria, Oman, Pakistan, Palestine, Poland, Saudi Arabia, South Africa, Sri Lanka, Sudan, Swaziland, Türkiye, UAE, UK, Yemen, Zimbabwe).
- Total feedback received from 123 participants

**Please rate the following aspects of the session**

Excellent Very good Good Satisfactory Poor



Did you find it useful  
123 responses



### Testimonials

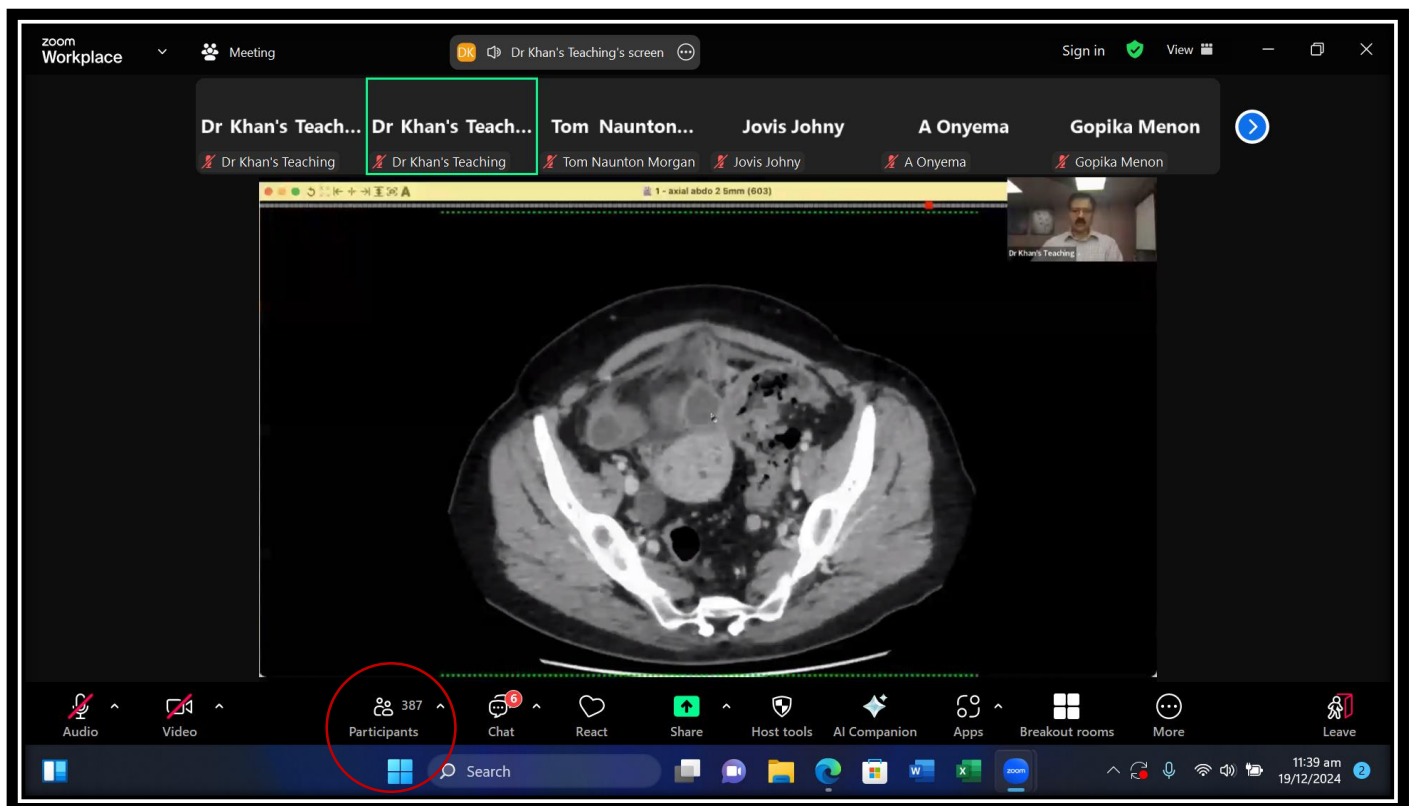
- The lecture was truly exceptional, with a diverse range of fascinating cases that were explained with great insight (Pakistan).
- The outstanding teaching approach "as usual". Thank you Dr. Khan's teaching for your great efforts (Sudan).
- Dr. Khan, we are so grateful for this great way of teaching (Iraq).
- The method of case presentation and approach used to cover important learning points for each case was useful (Egypt).
- Truly Amazing teaching, brilliant cases by Dr. Khan! Very grateful (Pakistan).
- Giving spots in a presentation format for each case was useful! (Netherlands).
- The search patterns demonstrated for bowel lesions were useful (Zimbabwe).
- Brilliant, so helpful (UK).
- Awesome (Indonesia).
- Extremely satisfy with this wonderful cases (Sudan).
- Nice and interesting case discussion on various abdominal emergency CT findings (Malaysia).
- Very useful. Thanks so much (Argentina).
- Thank you for the excellent teaching (South Africa).
- Absolutely wonderful session (India).
- Great cases and explanation (Bahrain).
- Coverage of the whole spectrum of acute abdomen was useful (Kuwait).
- Dr. Khan's explanations were most useful (South Africa).
- The extensive teaching style was most useful (Nigeria).
- Very informative and great learning experience (Egypt).
- Very informative cases (Palestine).
- We want more sessions with an awesome Dr. Khan (Sudan).

## DKT FRCR 2B Practice Viva (Session 85) - DKT Spotlight Series Mastering CT in Acute Abdomen (2/2)

- Various emergency abdominal cases were useful (Malaysia).
- It was perfect (UAE).
- Emergency, exam similar cases were most useful (Egypt).
- Great cases (Zimbabwe).
- Complete following description of case after student's description was useful (Pakistan).
- Very good cases (UAE).
- Cases approach was useful (Egypt).
- Rare cases were most useful (UAE).
- Interesting cases (South Africa).
- Very, very improved myself (Yemen).
- Cases were excellent (Pakistan).
- Good variety of cases (Malaysia).
- Every case is important and new to us (UAE).
- Nice and elaborative (Pakistan).
- Amazing cases (Pakistan).
- Pictures and information were useful (Sudan).
- Content and delivery was useful (UK).
- Presentation style was most useful (UK).
- All of it was very useful & highly valuable (Egypt).
- Cases and explanation was very nice (Pakistan).
- Very good (UK).
- The viva cases were most useful (Yemen).
- Interactive session (Canada).
- Type and number of cases were useful (Pakistan).
- Very well prepared cases (Turkey).
- Very interesting cases (Egypt).
- All pathologies seen were important (Pakistan).
- Awesome (India).
- All lecture was useful (Saudi Arabia).
- Very interesting cases (UK).
- Wonderful cases (Libya).
- Amazing cases (Iraq).
- Everything is just excellent (Pakistan).
- Amazing cases (Kuwait).
- Teaching sessions in between case presentations were useful (UK).
- Very illustrative (Egypt).
- Good exam cases and explanation were useful (UK).
- Excellent cases (Iraq).
- Brilliant cases (South Africa).
- All lecture part is helpful (Sudan).
- It was perfect (UAE).
- Please keep doing the good work (UK).
- Amazing (Yemen).
- More than excellent (Yemen).
- Best (Iraq).
- Very informative (UAE).
- Very excellent (Libya).
- Brilliant teaching (South Africa).
- Excellent learning (Pakistan).

## DKT FRCR 2B Practice Viva (Session 85) - DKT Spotlight Series Mastering CT in Acute Abdomen (2/2)

- Great (UK).
- Excellent teaching by Dr. Khan, nice cases (Pakistan).
- Fantastic (UK).
- Wonderful session (Kuwait).
- Great session (UK).
- Highly impressive (Iraq).
- Excellent teaching session (Nigeria).
- As always it's very informative (UK).
- Wonderful session (Pakistan).



# DKT FRCR 2B Practice Viva (Session 85) - DKT Spotlight Series Mastering CT in Acute Abdomen (2/2)

zoom Workplace Meeting Dr Khan's Teaching's screen Sign in View

Dr Khan's Teach... Dr Khan's Teach... Tom Naunton... Jovis Johnny A Onyema Gopika Menon

Dr Khan's Teaching Dr Khan's Teaching Tom Naunton Morgan Jovis Johnny A Onyema Gopika Menon

### The pubic tubercle: a CT landmark in groin hernia

The image shows a CT scan of the pelvis with labels for Direct Inguinal Hernia, Indirect Inguinal Hernia, and Femoral Hernia. An anatomical diagram of the right hemipelvis shows the pubic tubercle and its relationship to the inguinal canal. The CT scan shows the pubic tubercle as a landmark for identifying the type of groin hernia. The diagram shows the pubic tubercle as a landmark for identifying the type of groin hernia.

Delabrousse, E., Denué, P.O., Aubry, S. et al. The pubic tubercle: a CT landmark in groin hernia. *Abdom Imaging* 32, 803–806 (2007)

Audio Video Participants 373 Chat React Share Host tools AI Companion Apps Breakout rooms More Leave

10:57 am 19/12/2024

zoom Workplace Meeting Dr Khan's Teaching's screen Sign in View

Dr Khan's Teach... Dr Khan's Teach... Tom Naunton... Jovis Johnny A Onyema Gopika Menon

Dr Khan's Teaching Dr Khan's Teaching Tom Naunton Morgan Jovis Johnny A Onyema Gopika Menon

### Inferior epigastric Artery

The image shows an anatomical diagram of the inferior epigastric artery and a CT scan of the abdomen. The diagram shows the inferior epigastric artery as a branch of the external iliac artery. The CT scan shows the inferior epigastric artery as a branch of the external iliac artery.

Case courtesy of Craig Hacking, Radiopaedia.org, rID: 81909

Audio Video Participants 368 Chat React Share Host tools AI Companion Apps Breakout rooms More Leave

10:54 am 19/12/2024

=====XX=====XX=====